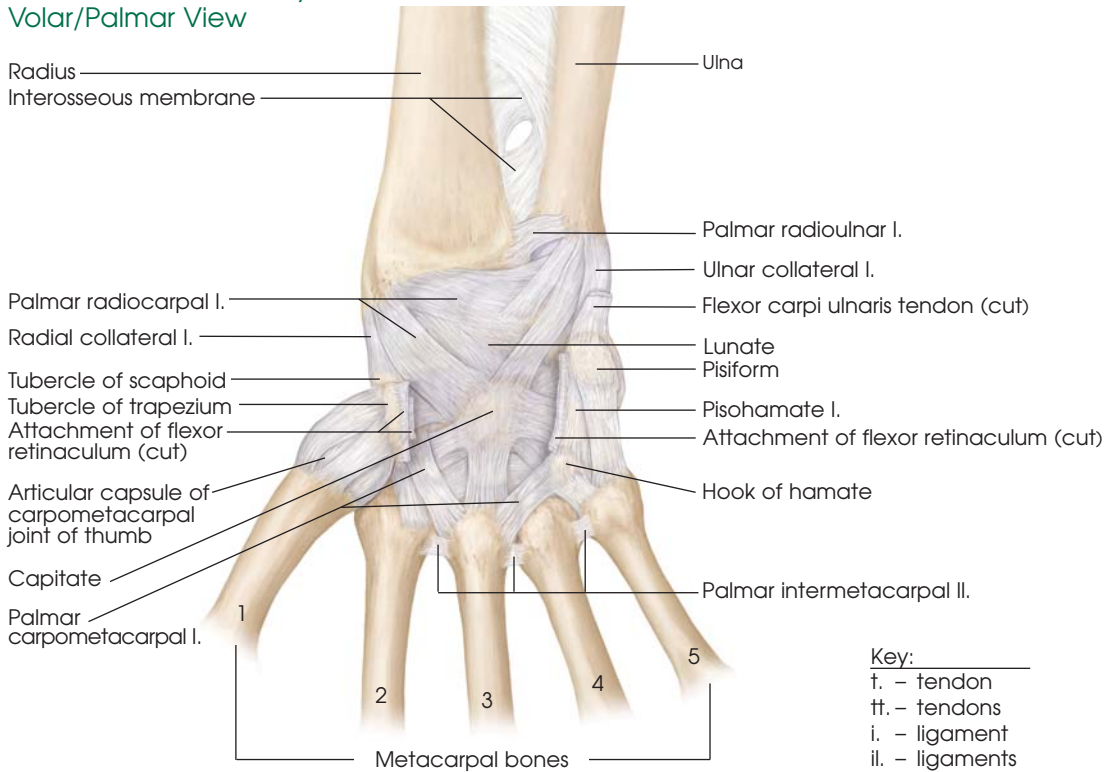
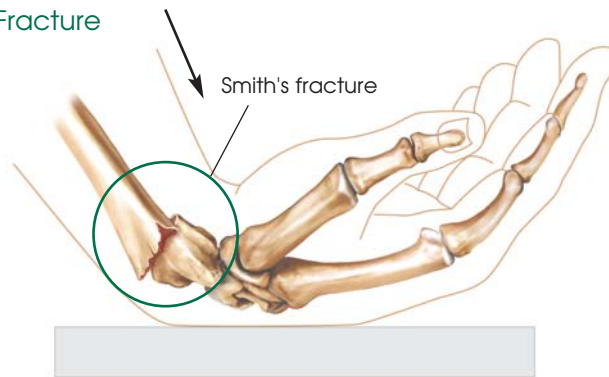


# Smith's Wrist Fracture

## Normal Hand Anatomy: Volar/Palmar View



## Smith's Fracture



**Smith's Wrist Fracture** is a break at the end of the radius bone of the forearm, close to the wrist. The break is usually due to a fall on an outstretched hand or can occur when the wrist is bent all the way forward. Symptoms can include pain, tenderness, swelling, bruising or deformity of the wrist (looking crooked or oddly bent).

## Common Treatment Options

- Surgery (called ORIF - Open Reduction and Internal Fixation) is usually performed to secure alignment of the bones in the proper position.
- A cast may be used to ensure alignment as the bone heals, but requires regular X-rays to ensure proper healing.
- To treat the symptoms, ice, elevation and pain medication may be recommended.
- Avoid smoking and nonsteroidal medications which can slow bone healing.

Notes:

---

---

---

---

---

---

---

---

---

---

---

---

---

---

---

---

---

---

---

---

---

---

---

---

---

Contact information

